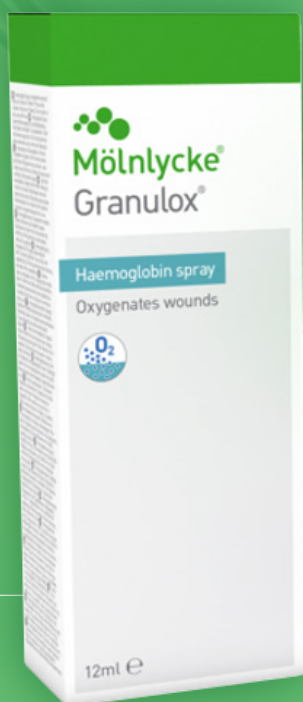

GRANULOX® (TOPICAL HAEMOGLOBIN SPRAY) IN THE MANAGEMENT OF HARD-TO-HEAL WOUNDS: CLINICAL EXPERIENCES FROM AROUND THE WORLD



Published by

Wounds International
A division of Omniamed Communications Ltd
108 Cannon Street
London EC4N 6EU, UK
Tel: +44 (0)20 3735 8244
Email: info@omniamed.com
www.woundsinternational.com

WOUNDS | INTERNATIONAL

© Wounds International, 2024

Suggested citation

Davies P (2024), *Granulox (topical haemoglobin spray) in the management of hard-to-heal wounds: clinical experiences from around the world*. Wounds International, London. Available to download from www.woundsinternational.com

All rights reserved ©2024. No reproduction, copy or transmission of this publication may be made without written permission.

All rights reserved. No reproduction, transmission or copying of this document is allowed without written permission. No part of this document may be reproduced, stored in a retrieval system, or transmitted in any form or by any means (mechanical, electronic, photocopying, recording or otherwise) without the prior written permission of Mölnlycke Health Care AB or in accordance with the relevant copyright legislation. Although the author has taken great care to ensure accuracy, neither the author nor Mölnlycke Health Care AB will be liable for any errors of omission or accuracy in this document. Any products referred to by the author should be used according to the instructions for use supplied with them.

The Mölnlycke and Granulox trademarks, names and logos are registered globally to one or more of the Mölnlycke Health Care Group of Companies.

Supported by an educational grant from Mölnlycke Health Care.



Declaration of interest

This paper is authored by an employee of Mölnlycke Health Care. It has not been subject to double-blind peer review.

Contents

Role of oxygen in wound healing	3
Effect of hypoxia on wound healing	4
Delivering additional oxygen to the hypoxic wound	5
Granulox® (topical haemoglobin spray)	6
Case studies	9
Concluding remarks	21
References	22

About the author

Phil Davies has more than 35 years' experience working in healthcare-related industries. During that time, he has authored and contributed to numerous peer-reviewed journal articles and conference presentations (oral and poster) relating to wound care and other areas of healthcare. Phil was awarded a BSc (Hons) Medical Cell Biology and Biochemistry by the University of Liverpool (UK) in 1989.

Role of oxygen in wound healing

The body's first defence against microorganisms and trauma is the skin. When the skin is damaged, its natural protective barrier function is impeded. The tightly regulated biological process of wound healing is critical to the restoration of the skin's barrier function (Han and Ceilley et al, 2017; Singh et al, 2017). While most wounds typically heal within days or weeks, others (often referred to as 'chronic' or 'hard-to-heal') can persist for months and even years (Frykberg and Banks, 2015). These hard-to-heal wounds become 'stalled', most commonly in the inflammatory phase of the healing process, and generally require clinical intervention to achieve healing (Hampton, 2015). The risk of wound chronicity is associated with underlying pathologies and comorbidities (e.g. diabetes mellitus, venous insufficiency, immobility, immune suppression, increasing age, malnutrition) and some clinical interventions (e.g. steroid therapy; Dermidova-Rice et al, 2012).

Oxygen is a vital requirement for almost every step in the wound healing process, including angiogenesis, re-vascularisation, synthesis of connective tissue and resistance to infection (Figure 1; Chadwick et al, 2019).

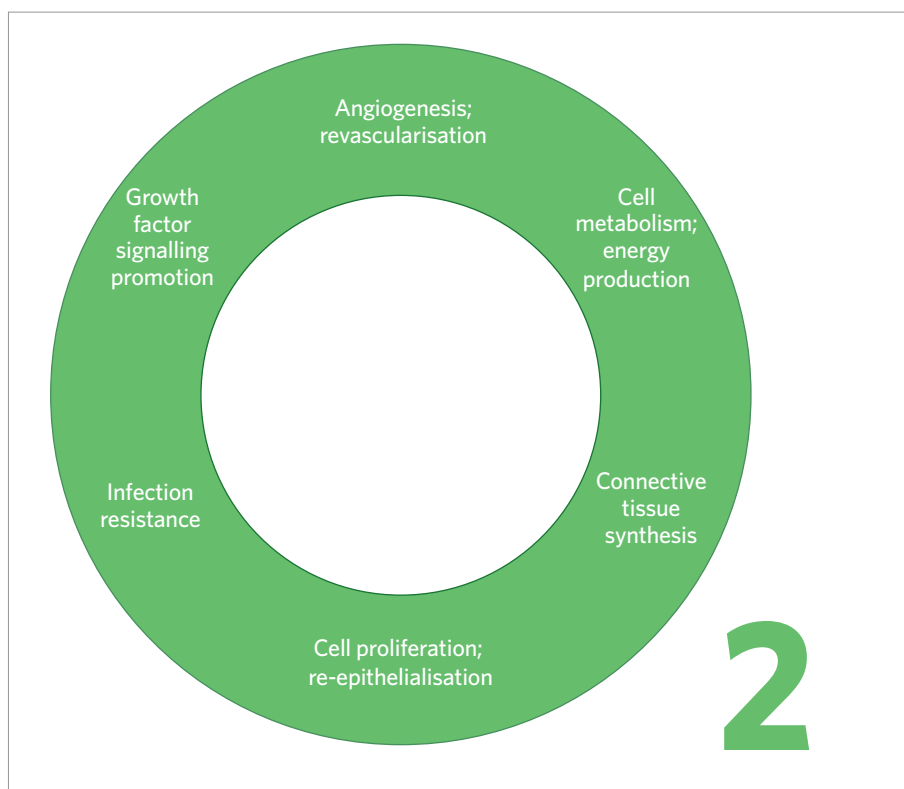


Figure 1. Key roles of oxygen in the wound healing process (adapted from Chadwick et al, 2019)

Effect of hypoxia on wound healing

When injury occurs, a wound quickly becomes hypoxic, typically with an increasing oxygen gradient towards the intact tissue (Bishop, 2008). Hypoxia may be due to an increased oxygen demand because of the high metabolic activity of a healing wound, but may also be affected by the partial oxygen pressure of the surrounding tissue and suboptimal circulating blood supply, e.g. injured microcirculation, diffusive constraints due to oedema, poor blood circulation (peripheral arterial disease (PAD)), or oxygen consumption by bacterial biofilm. Initially, acute hypoxia acts as a signal to promote the healing process (Rutherford et al, 2014; Strowitzki et al, 2019) but prolonged hypoxia [Figure 2] is detrimental to healing progression (Gottrup et al, 2017; Chadwick et al, 2019; Younis, 2020). In chronic wounds sustained oxygen deficit at the wound bed has been shown, with an associated detrimental effect on wound healing (Dissemond et al, 2015).

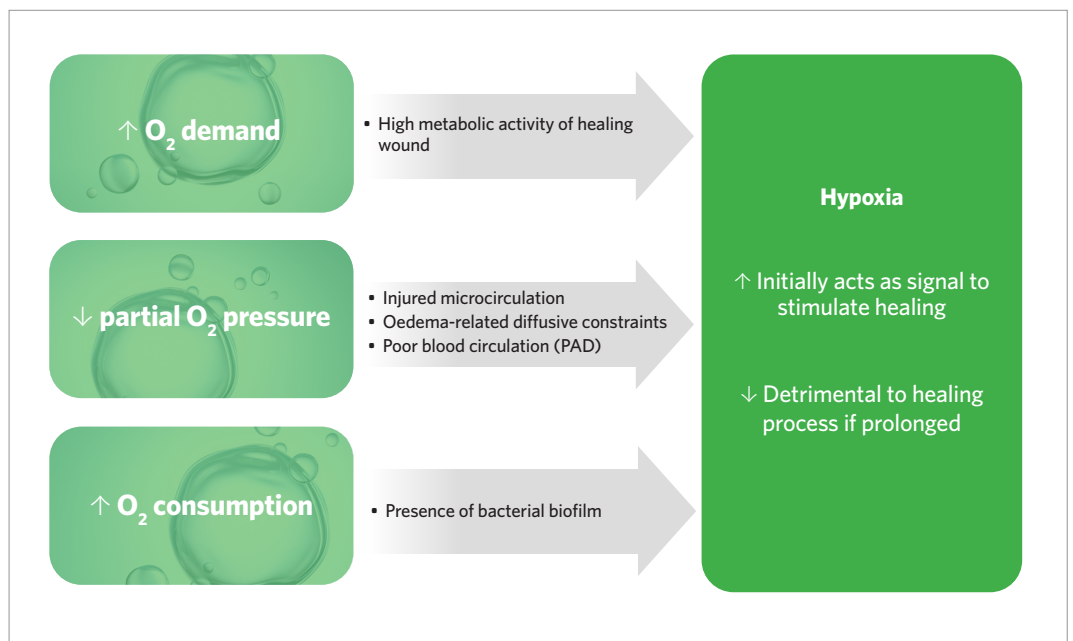


Figure 2. Impact of hypoxia on wound healing (Bishop, 2008; Dissemond et al, 2015; Gottrup et al, 2015; Dissemond et al, 2017)

Delivering additional oxygen to the hypoxic wound

The availability of oxygen is a strong predictor for wound healing outcome; just 3% of wounds with an extremely low oxygen concentration heal, compared to 95% of wounds with a normal oxygen concentration (Hauser, 1987). Therefore, supplying additional oxygen directly to the wound bed, an intervention that has been used in wound care for many years, may help promote healing. The goal of appropriate oxygen therapy is to transfer sufficient oxygen to interstitial tissues to maintain wound repair processes throughout the healing trajectory (Kruger et al, 2020). However, the mechanism by which oxygen is delivered to the wound is a critical factor in achieving successful outcomes.

The first type of oxygen therapy to be used in the field of wound care was hyperbaric oxygen therapy (HBOT) back in the 1960s (Gottrup et al, 2017), but this systemic intervention requires substantial dedicated infrastructure and is not widely available. Nowadays, a variety of portable products are available to deliver topical oxygen therapy (TOT) to wounds (Dissemond et al, 2015; Gottrup et al, 2017; Chadwick et al, 2019).

TOT aims to increase oxygen levels at the wound site, thus facilitating the reversal of localised hypoxia, particularly for wounds that have failed to respond to standard care. Unlike systemic oxygen therapy (i.e. HBOT), TOT does not rely on the vascular system to deliver oxygen to the wound. Several randomised controlled trials and systematic reviews with meta-analyses have validated many aspects of TOT, leading the American Diabetes Association (ADA) to give TOT the highest level evidence rating in its 'Standards of Care' guideline (ADA, 2023).

Furthermore, in its updated guidelines, the International Working Group on the Diabetic Foot (IWGDF) points out that "the evidence on topical oxygen has substantially expanded in the last four years", leading to the recommendation "Consider the use of topical oxygen as an adjunct therapy to standard of care for wound healing in people with diabetes-related foot ulcers where standard of care alone has failed and resources exist to support this intervention" (IWGDF, 2023).

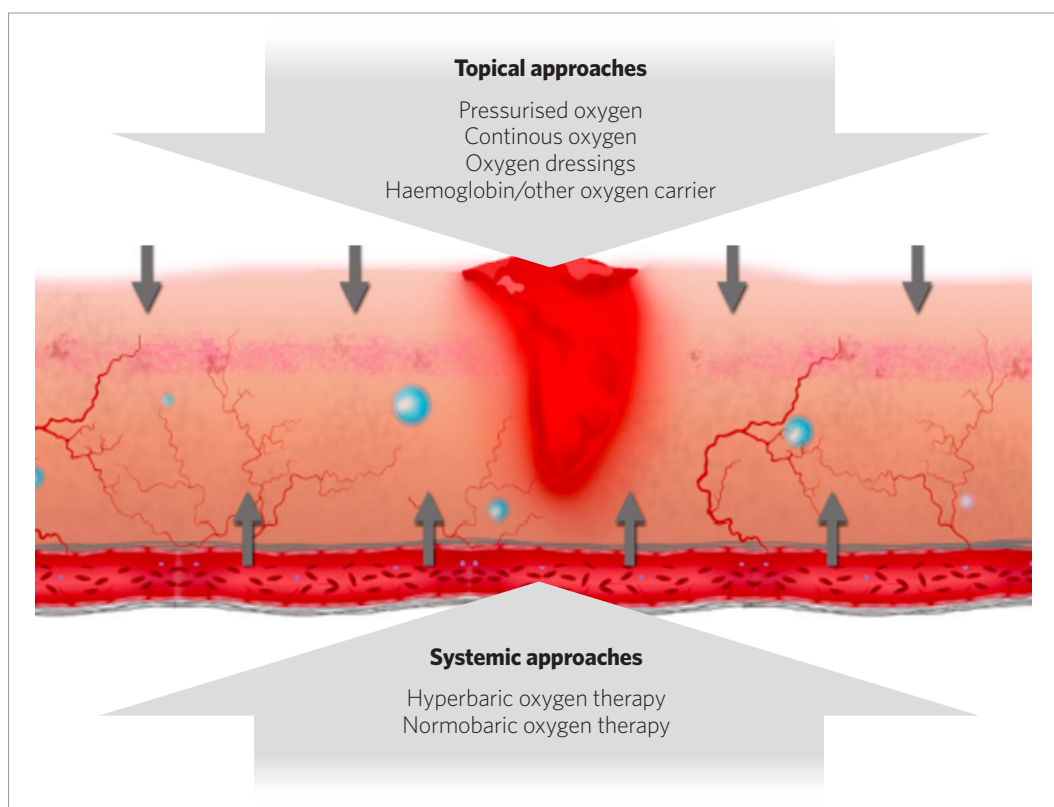
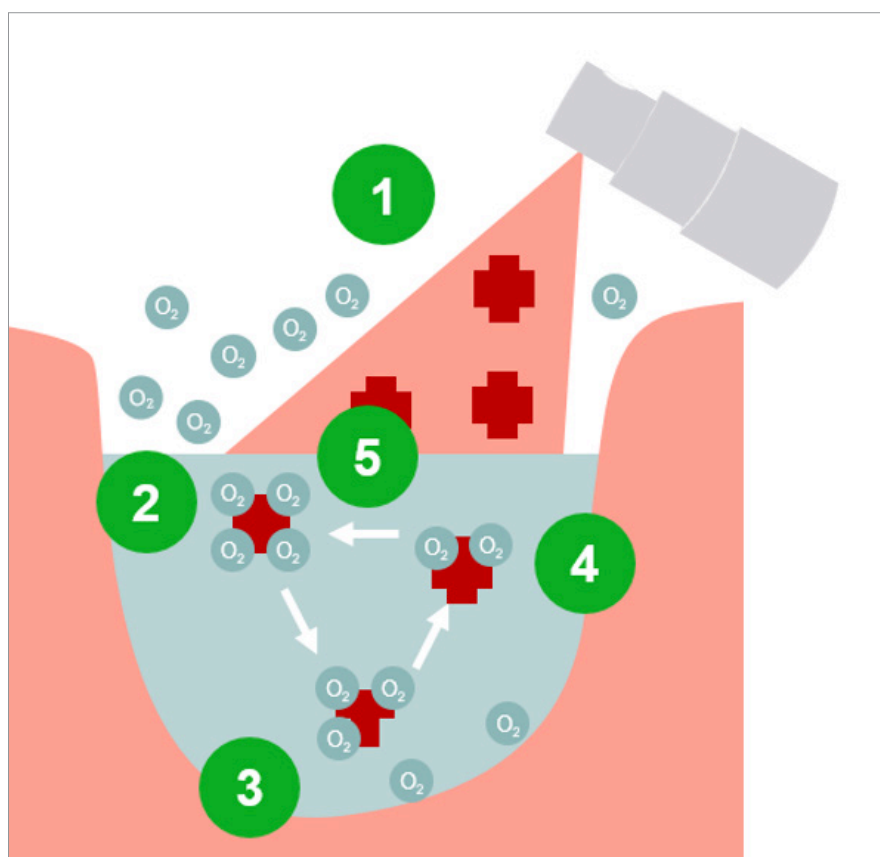


Figure 3. Therapeutic approaches to deliver additional oxygen to the wound (Dissemond et al, 2015)

Granulox® (topical haemoglobin spray)

Granulox® is a topical haemoglobin spray that is designed to improve the oxygen supply to chronic wounds through simplified diffusion, thereby promoting wound healing. When Granulox® is applied to the wound bed, the haemoglobin binds oxygen from the surrounding air and transports it to the wound bed where it diffuses into the cells (Dissemond et al, 2015) **[Figure 4]**. Granulox® is indicated for the treatment of chronic diabetes-related foot ulcers, venous, arterial and mixed leg ulcers, pressure ulcers and post-surgical wounds. It can also be used to help facilitate the healing of sloughy and infected wounds.

Figure 4. Mode of action of Granulox®. **[1]** The product is sprayed onto the wound. Haemoglobin (Hb) diffuses into the wound exudate and starts to bind oxygen. **[2]** Oxygen is readily available at the wound surface; Hb binds more oxygen. **[3]** Hb diffuses within the wound bed. **[4]** Driven by the oxygen gradient, Hb releases oxygen in hypoxic regions, thus enhancing oxygen diffusion in the wound bed. **[5]** The process is reversible and Hb can absorb more oxygen when available (Dissemond et al, 2015)



The following sub-sections summarise the findings of the key clinical studies that have been undertaken to evaluate the efficacy of Granulox® with regard to wound healing, pain reduction and sloughy tissue presence.

Wound healing

A randomised controlled trial undertaken in the Czech Republic assessed the impact of introducing Granulox® into the standard care regime (nanofibre dressing, gauze fixation and short-stretch compression bandaging), as compared to standard care alone, in the treatment of chronic venous leg ulcers. After 13 weeks of treatment, those ulcers treated with Granulox® demonstrated an average 53% reduction in size, as compared to a 21% increase in size in those ulcers treated with just standard care (i.e. no Granulox®) (Arenbergerova et al, 2013).

In other clinical studies undertaken in the UK, a regime involving the addition of Granulox® to standard care was associated with better wound healing rates, compared to standard care alone (**Table 1**; Hunt and Elg, 2016; Hunt and Elg, 2017; Hunt et al, 2018).



Table 1. Clinical studies of Granulox® undertaken in the UK

Reference	Design methodology	Main outcome measures	Main results
Hunt and Elg, 2016	Chronic diabetes-related foot ulcer Intervention group (n=20): Granulox® plus standard care (pre-evaluation dressing type with off-loading if required) applied twice weekly Retrospective control group (n=20): standard care. Twice-weekly dressing changes	Reduction in wound size or wound closure over a 28-week treatment period	Reduction in wound size at 28 weeks: 95% (intervention group) vs 63% (control) (p=0.02) Healing time was 50% shorter in the intervention group Twice as many ulcers healed at weeks 8-16 in the intervention group
Hunt and Elg, 2017	Hard-to heal wounds (e.g. pressure ulcer, leg ulcer, diabetic foot ulcer, burn, surgical and traumatic) Intervention group: Granulox® plus standard care (pre-evaluation dressing) applied twice weekly (n=50) Retrospective control group: standard care. Twice-weekly dressing changes (n=50)	Wound healing over a 26-week treatment period	Wounds healed at 26 weeks: 90% (45/50) intervention vs 38% (19/50) control (p<0.001) Mean time to complete wound healing: 6.6 weeks (range 3-22-weeks) intervention vs 11.4 weeks control (range 3-25 weeks), (p=0.01)
Hunt et al, 2018	Sloughy wounds (burn, foot ulcer, leg ulcer, pressure ulcer, surgical wound, traumatic wound) Intervention group: Granulox® plus standard care, applied twice weekly (n=100) Retrospective control group: standard care. Twice-weekly dressing changes (n=100)	Wound healing over a 26-week treatment period	Wounds completely healed at 26 weeks: 94% intervention group vs 63% control group Mean wound size reduction: 98% intervention group vs control group 74% (p=0.002) Mean slough coverage of wound: 1% intervention group vs 29% control group (p<0.001)

Wound pain

Among other burdensome complications, patients with hard-to-heal wounds may experience pain, which can negatively impact on their quality of life. Hypoxic signalling induced by reduced vascularity can result in increased hypersensitivity and pain (Da Vitoria Lobo et al, 2022), hence interventions that are aimed at addressing hypoxia can be expected to reduce pain. In the clinical studies outlined in Table 1, reductions in pain were observed when Granulox® was used as an adjunct to standard wound care. For example, one study observed a 40% mean reduction in pain scores in patients receiving Granulox® plus standard of care compared to 13% in those receiving standard care alone after one week of treatment. By week four, this difference increased with an 86% mean reduction in pain scores in the Granulox® plus standard of care group compared with 16% in the standard care group (Hunt and Elg, 2017).

Sloughy tissue

In addition to observations of pain reduction in patients receiving treatment with Granulox®, the clinical studies outlined in Table 1 also demonstrated the topical haemoglobin spray to have an effect on sloughy tissue. For example, in the most recently undertaken study, 99% less slough was observed after four weeks of treatment with Granulox® in conjunction with standard care, compared to 33% less with standard care alone (Hunt et al, 2018).

Granulox® (topical haemoglobin spray) (Continued)

Cost-effectiveness

Wound duration (time to healing), frequency of dressing changes and occurrence of complications are fundamental to determining the value of interventions in wound care. A health economic study in the UK used real-life data from an interventional clinical study within a community setting (Hunt and Elg, 2017) to provide clarity on the impact of dressing costs and to demonstrate the cost-effectiveness of including Granulox® in the standard care treatment regimen for hard-to-heal wounds (pressure ulcers, leg ulcers, diabetes-related foot ulcers, burns, surgical and traumatic wounds), as compared to standard care alone. A de novo cost-effectiveness and break-even analysis were performed based on the study data, considering only wound care dressing costs and the total number of weeks the wounds were healed (i.e. no dressings applied) in each group. Dressing costs for the Granulox® plus standard care group were £6,953, compared to £9,547 for the standard care only group (Elg and Bothma, 2019).

The results of the clinical studies described above demonstrate that the addition of Granulox® to standard wound care can decrease time to healing and, thereby, reduce the frequency of dressing changes and the incidence of complications compared to a wound care regime that does not include the topical haemoglobin spray. Collectively, the clinical and health economic evidence suggests that Granulox® (as an adjunct to standard care) supports the achievement of better clinical outcomes at a reduced cost, thereby providing a dominant treatment option when compared to standard care alone.

CASE STUDIES

While randomised controlled trials, systematic reviews and meta-analyses are considered to be the 'gold standards', case studies can be used to capture 'real world' clinical practice. On this basis, it could be argued that all available evidence across the so-called evidence hierarchy should be considered and evaluated by wound care practitioners. Although case studies are generally ranked relatively low in comparison to other forms of research, they are a useful means of illustrating clinical challenges, sharing 'real-life' experiences and examining real-world clinical practice. For these reasons, case studies are much valued as educational tools (Timmons, 2006).

The following pages detail a number of cases in which Granulox® was considered by the reporting clinicians as a suitable intervention to expedite the healing of difficult-to-heal wounds.



Case study 1. Diabetes-related foot ulcer







Patient and wound history

- 81-year-old male
- Medical history of type 2 diabetes mellitus and peripheral arterial disease
- Diabetes-related foot ulcer, located on the heel of the left foot; present for five months
- Prior to the case study, the ulcer had been treated with a povidone iodine dressing.

Intervention and treatment regime

- A detailed wound evaluation was completed at a baseline assessment and at four further scheduled visits over a period of 30 days
- Wound dressings were changed at each study visit according to local clinical practice
- At each dressing change throughout the study, mechanical debridement was performed using a pad moistened with an antimicrobial wound irrigation solution
- Prior to dressing application, the ulcer was coated with a thin film of Granulox[®], then dressed with Melgisorb[®] Ag (silver-containing alginate dressing).

Wound progression (photographs taken post-debridement/cleansing)

	Start of evaluation (Day 1)	Day 4	Day 9	Day 30
				
Wound area ¹	3.4cm ²	2.3cm ² (↓32.4%)	1.8cm ² (↓47.1%)	1.3cm ² (↓61.8%)
Wound depth	0.7cm	0.7cm	0.7cm	0.5cm
Signs of infection	None	None	None	None
Viable tissue	90%	90%	90%	90%
Exudate	Moderate; non-viscous; clear/serous	Low; non-viscous; clear/serous	Low; non-viscous; clear/serous	Low; non-viscous; clear/serous
Peri-wound	Healthy	Healthy	Healthy	Healthy
Pain score ²	6	4	4	4

¹Percentage changes in wound area relative to start of evaluation; ²On dressing removal based on a scale of 0 (no pain) to 10 (worst pain imaginable)

Perspective

- A five-month-old diabetes-related foot ulcer reduced in size by 62% within five weeks of commencing treatment with Granulox[®]. The ulcer increased in size (to 2.3cm²) within one week of Granulox[®] treatment being stopped
- Granulox[®] was easy and safe to use.



Marino Ciliberti, Director, Tissue Repair Company Network, Gragnano, Campania, Italy

Case study 2. Diabetes-related foot ulcer



Patient and wound history

- 70-year-old female
- Spinal surgery three years prior to presentation; continued to suffer from post-operative pain that required non-steroidal anti-inflammatory drug (NSAID) medication (diclofenac). No history of immunosuppression or evidence of venous enlargement or vascular disease in the patient's leg. Due to a suspected persistent low-grade infection, antibiotics were prescribed. In addition, NSAID medication was stopped to determine if it was preventing the progression of healing, but the patient's pain level increased, and she became depressed, so it was re-commenced
- Diabetes-related foot ulcer, located on the left malleolus; present for 19 months
- The peri-wound skin was healthy with slight inflammation, but the wound edge had a punched-out appearance
- Prior to the study, the ulcer had been treated with lignocaine (pre-debridement), an antimicrobial emollient and various wound dressings (hydrogel, nanocrystalline silver-coated polyethylene net, foam, alginate, hydroactive capillary action, honey-based, cadexomer iodine).

Intervention and treatment regime

- A detailed wound evaluation was completed at a baseline assessment and at 10 further visits over a treatment period of 70 days
- Wound dressings were changed at each study visit according to local clinical practice. At each dressing change throughout the study, the ulcer was cleansed with antimicrobial wound irrigation solution and conservative sharp wound debridement was performed to achieve pin-point bleeding to stimulate wound healing. A barrier wipe was used to protect the peri-wound skin
- Prior to dressing application, the ulcer was coated with a thin film of Granulox[®], then dressed with Mepilex[®] Border Flex (foam dressing). At day 42 of the study, a nanocrystalline silver-coated dressing replaced Mepilex[®] Border Flex for seven days due to the presence of hyper-granulation tissue. Throughout the study, a single layer of Tubigrip[®] (elasticated tubular support bandage) was used for fixation and light compression, as the patient was unable to tolerate full compression therapy.

Wound progression (photographs taken post-debridement/cleansing)

	Start of evaluation (Day 1)	Day 21	Day 62	Day 70
Wound area ¹	1.3cm ²	0.35cm ² (↓73.0%)	0.25cm ² (↓88.5%)	Healed
Signs of infection	↑ Pain	None	None	-
Viable tissue	100%	100%	100%	-
Exudate	None	None	None	-
Peri-wound	Healthy	Erythema (mild)	Healthy	Healthy
Pain score ²	4	3	2	-

¹Percentage changes in wound area relative to start of evaluation; ² On dressing removal based on a scale of 0 (no pain) to 10 (worst pain imaginable)

Perspective

- A five-month-old diabetes-related foot ulcer reduced in size by 62% within 10 weeks of commencing treatment with Granulox[®]
- Granulox[®] was easy to use
- The patient was delighted with the outcome – she was finally healed and pain-free.



Sharon Cassidy, Clinical Nurse Specialist/Manager, SOS Nursing Wound Clinic, Christchurch, New Zealand

Case study 3. Diabetes-related foot ulcer







Patient and wound history

- 73-year-old male
- Medical history of type 2 diabetes mellitus; osteoarthritis that had resulted in hip replacement surgery and amputation of third/fourth toes on the right foot; smoker; sensitivities to previously used dressings and adhesives
- Ulcer, located on the second metatarsal area of the plantar right foot; present for nine months
- Prior to the study, the ulcer had been treated with simple gauze dressings.

Intervention and treatment regime

- A detailed wound evaluation was completed at a baseline assessment and at six further scheduled visits over a period of 91 days
- Wound dressings were changed at each study visit according to local clinical practice
- At each dressing change throughout the study, non-viable tissue was debrided (sharp), the wound was cleansed with Granudacyn® Wound Irrigation Solution (hypochlorous acid) before being coated with a thin film of Granulox®, then dressed with Exufiber® Ag+ (silver-containing fibre; primary dressing) and Mepilex® Border Lite (self-adherent soft silicone foam; secondary dressing) under a retention bandage. After 14 days, both dressings were replaced with gauze
- Off-loading (orthotic shoe) was provided.

Wound progression (photographs taken post-debridement/cleansing)

	Start of evaluation (Day 1)	Day 14	Day 42	Day 91
				
Wound area ¹	1.5cm ²	1.9cm ² (↑27.0%)	0.8cm ² (↓47.01%)	Healed
Wound depth	0.1cm (mean)	0.1cm (mean)	0.1cm (mean)	-
Signs of infection	None	None	None ²	-
Viable tissue	0%	10%	40%	-
Exudate	Low; non-viscous; clear/serous	Low; non-viscous; clear/serous	Low; non-viscous; clear/serous	-
Peri-wound	Healthy	Mild maceration	Healthy	Healthy
Pain score ³	0	0	0	-

¹Percentage changes in wound area relative to start of evaluation; ²Antibiotics prescribed for an unrelated infection;

³On dressing removal based on a scale of 0 (no pain) to 100 (worst pain imaginable)

Perspective

- Following the introduction of Granulox®, a long-standing foot ulcer progressed to complete healing within 13 weeks of commencing treatment.



Nikolaos Tentolouris, First Department of Propedeutic Internal Medicine, Medical School, National and Kapodistrian University of Athens, Laiko General Hospital, Athens, Greece

Case study 4. Diabetes-related foot ulcer







Patient and wound history

- 56-year-old male
- Medical history of type 2 diabetes mellitus
- Ulcer, located on the hallux area of left foot plantar; present for 45 days
- Prior to the study, the ulcer had been treated with simple gauze dressings.

Intervention and treatment regime

- A detailed wound evaluation was completed at a baseline assessment and at seven further scheduled visits over a period of 109 days
- Wound dressings were changed at each study visit according to local clinical practice
- At each dressing change throughout the study, non-viable tissue was debrided (sharp), the wound was cleansed with Granudacyn® Wound Irrigation Solution (hypochlorous acid) before being coated with a thin film of Granulox®, then dressed with Mepilex® Border Lite (self-adherent soft silicone foam dressing). Antibiotics prescribed. Dressings initially changed every two days; from day 81 onwards, dressings changed daily.

Wound progression (photographs taken post-debridement/cleansing)

	Start of evaluation (Day 1)	Day 32	Day 81	Day 109
				
Wound area ¹	3.7cm ²	2.9cm ² (↓22.0%)	1.8cm ² (↓51.0%)	0.5cm ² (↓86.0%)
Wound depth	0 - 0.2cm	0 - 0.1cm	0.1 - 0.3cm	0 - 0.3cm
Signs of infection	Yes ²	Yes ²	Reduced	None
Viable tissue	5%	60%	90%	90%
Exudate	High; non-viscous; purulent	High; non-viscous; clear/serous	Low; non-viscous; clear/serous	Low; non-viscous; clear/serous
Peri-wound	Not healthy ³	Deteriorated	Healthy	Healthy
Pain score ⁴	20	0	0	0

¹ Percentage changes in wound area relative to start of evaluation; ² Increased pain/warmth/exudation, erythema, oedema and malodour (all mild); ³ Mildly macerated/dryness/erythema/excoriation/blistering; ⁴ On dressing removal based on a scale of 0 (no pain) to 100 (worst pain imaginable)

Perspective

- Following the introduction of Granulox®, the condition of this challenging foot ulcer had improved within 16 weeks of commencing treatment.



Nikolaos Tentouris, First Department of Propedeutic Internal Medicine, Medical School, National and Kapodistrian University of Athens, Laiko General Hospital, Athens, Greece



Case study 5. Pressure ulcer




Patient and wound history

- 63-year-old female
- Medical history of multiple sclerosis and type 2 diabetes mellitus; long-term urinary catheterisation with bypassing; bedbound (sits up for extended periods)
- Ulcer, located on the sacrum; present for four years
- Historically, care provision included pressure ulcer prevention advice, provision of a hybrid air mattress and a lateral turning platform, plus the use of conventional dressings. Immediately prior to the study, the wound had been treated with an alcohol-free liquid barrier film, a silver-containing fibre dressing and a polyurethane foam dressing.

Intervention and treatment regime

- A detailed wound evaluation was completed at a baseline assessment and at weekly visits to the patient's home over a period of 98 days
- Wound dressings were changed daily according to local clinical practice
- Up to day 77 of the study, the ulcer was coated with a thin film of Granulox[®], then dressed with a cut-to-size fibre ribbon (primary dressing) and a polyurethane foam (secondary) dressing. Granulox[®] was discontinued at day 77 (no longer required).

Wound progression (photographs taken post-debridement/cleansing)

	Start of evaluation (Day 1)	Day 42	Day 98
			
Wound area ¹	32.2cm ²	26.0cm ² (↓19.3%)	15.0cm ² (↓53.4%)
Wound depth	1.0cm	0.5cm	0.5cm
Signs of infection	None	None	None
Viable tissue	100%	100%	95%
Exudate	High; non-viscous; clear/serous	Moderate; non-viscous; clear/serous	Moderate; non-viscous; clear/serous
Peri-wound	Maceration	Maceration	Maceration
Pain score ²	10	5	5

¹Percentage changes in wound area relative to start of evaluation; ²On dressing removal based on a scale of 0 (no pain) to 100 (worst pain imaginable)

Perspective

- A four-year-old pressure ulcer significantly improved following the introduction of Granulox[®] into the treatment regime. Healing was 'kick-started' within days. Notably, when treatment with Granulox[®] was stopped, the wound continued to improve
- Pain was reduced, allowing control measures to be reviewed and importantly permitted the patient to spend extended periods of time sitting up
- When the patient was shown a photograph of the study wound, she was happy with the outcome.

Katie Jeffrey, Development Community Tissue Viability Nurse, Virgin Care – North Kent, Sittingbourne Community Hospital, Sittingbourne, UK



Case study 6. Surgical wound



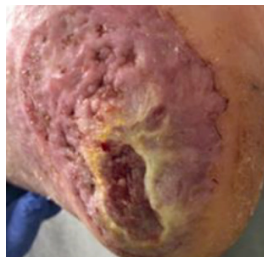
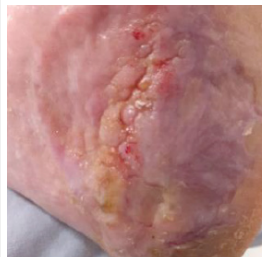
Patient and wound history

- 70-year-old male
- At the first presentation, the heel was bleeding; antibiotics were prescribed and dressings applied; after three months, the wound had progressed to a non-healing ulcer. Following a skin biopsy, a malignant melanoma was diagnosed; five months after the first symptoms presented, a wide local excision of the sole of the foot and heel was performed
- One month after the start of this case study, the patient had a tumour removed from the left groin; antibiotics were prescribed for an infection. Due to a diagnosis of metastatic disease involving unresectable non-regional lymph nodes, immunotherapy was commenced one year after the patient's original presentation
- Non-healing surgical wounds, located on the left heel; present for three months
- The edges of the wound were rolled with hyper-granulation tissue present
- Prior to the study, the wound had been treated with a variety of dressings and products (nanocrystalline silver-coated polyethylene net, cadexomer iodine, povidone iodine non-adherent keratin-containing gel, antimicrobial emollient and a wound irrigation solution).

Intervention and treatment regime

- A detailed wound evaluation was completed at a baseline assessment and regular follow-up visits over 170 days
- Wound dressings were changed twice weekly according to local clinical practice. At each dressing change throughout the study, the wound was cleansed and conservative sharp wound debridement was performed to achieve pin-point bleeding to stimulate wound healing. A barrier wipe was used to protect the peri-wound skin
- Prior to dressing application, the wound was coated with a thin film of Granulox[®], then dressed with Exufiber[®] Ag+ (gelling fibre; primary dressing) and Mepilex[®] Border Flex (foam; secondary dressing). At day 43 of the study, Exufiber[®] Ag+ was discontinued (no longer required). Throughout the study, Mefix[®] (adhesive tape) was used for additional fixation together with Tubifast[®] (tubular retention bandage). The patient declined compression therapy
- At each dressing change throughout the study, non-viable tissue was debrided (sharp), the wound was cleansed with an antimicrobial wound irrigation solution before being coated with a thin film of Granulox[®], then dressed with Exufiber[®] Ag+ (silver-containing fibre; primary dressing) and Mepilex[®] Border Lite (self-adherent soft silicone foam; secondary dressing) under a retention bandage. After 14 days, both dressings were replaced with a non-adherent primary dressing and gauze (secondary)
- Off-loading (orthotic shoe) was provided.

Wound progression (photographs taken post-debridement/cleansing)

	Start of evaluation (Day 1)	Day 20	Day 65	Day 170
				
Wound area ¹	13.1cm ²	19.25cm ² (↑46.9%)	3.5cm ² (↓73.3%)	Healed
Signs of infection	↑ Exudation	↑ Exudation	None	-
Viable tissue	100%	0%	25%	-
Exudate	Moderate; non-viscous; clear/serous	Moderate; non-viscous; clear/serous	Low; non-viscous; clear/serous	-
Peri-wound	Hyperkeratosis	Hyperkeratosis	Scar tissue	Scar tissue
Pain score ²	4	4	2	-

¹ Percentage changes in wound area relative to start of evaluation; ² On dressing removal based on a scale of 0 (no pain) to 10 (worst pain imaginable)

Perspective

- A three-month-old surgical wound healed within 24 weeks of commencing treatment with Granulox[®]
- While Granulox[®] was working at the cellular level, the clinician was able to focus on the bigger picture of what was happening in the wound bed and surrounding peri-wound region
- After being made aware of what Granulox[®] was and why it was being offered, the patient was excited to take part in the study. He was happy with the wound healing progress, seeing 'its angry red shade' become pinker and the wound in-fill with tissue. This improvement enabled him to walk on his foot, which helped keep his spirits up despite his deteriorating health.



Sharon Cassidy, Clinical Nurse Specialist/Manager, SOS Nursing Wound Clinic, Christchurch, New Zealand



Case study 7. Surgical wound

Patient and wound history

- 66-year-old male
- No relevant medical history but being treated for venous stasis
- The patient initially had ruptured his left Achilles tendon in 2016 in a work-place accident. V-Y reconstruction of the Achilles was originally performed in May 2017 but was complicated by infection, that required several scar revision surgeries
- Surgical wound, located on the left Achilles; present for three years
- Prior to the study the wound had been treated with several advanced wound dressings (nanocrystalline silver-containing, hydroactive capillary action, cadexomer iodine, honey-based, alginate and foam).

Intervention and treatment regime

- A detailed wound evaluation was completed at a baseline assessment and at 23 further scheduled visits over 57 days
- Wound dressings were changed twice weekly according to local clinical practice. At each dressing change throughout the study, the wound was cleansed with antimicrobial wound irrigation solution and conservative sharp wound debridement was performed to achieve pin-point bleeding to stimulate wound healing
- Prior to dressing application, the ulcer was coated with a thin layer of Granulox® and a barrier wipe was used over the wound edge and peri-wound skin for protection before being dressed with Mepore® (self-adhesive, absorbent dressing). A Tubifast® (tubular retention) stocking was used for added fixation. The patient would not agree to compression stockings. After 157 days, Granulox® treatment was stopped and a keratin-enriched gel dressing was applied to strengthen the newly formed skin and help prevent further skin breakdown.

Wound progression (photographs taken post-debridement/cleansing)

	Start of evaluation (Day 1)	Day 70	Day 119	Day 157
Wound area ¹	1.04cm ²	0.14cm ² (↓86%)	Cavity beneath wound surface observed	0.02cm ² (↓98%)
Signs of infection	None	None	None	None
Viable tissue	100%	100%	100%	100%
Exudation	None	None	None	None
Peri-wound	Maceration	Healthy	Healthy	Healthy
Pain score ²	0	0	0	0

¹Percentage changes in wound area relative to start of evaluation; ² On dressing removal based on a scale of 0 (no pain) to 10 (worst pain imaginable)

Perspective

- After exhausting all the advanced wound dressing options available, the clinician was excited to find a product that could finally take this wound to healing
- The patient said, "5 years after my initial accident, I am finally healed! and it's so good to be able to wear shoes again".



Sharon Cassidy, Clinical Nurse Specialist/Manager, SOS Nursing Wound Clinic, Christchurch, New Zealand



Case study 8. Traumatic wound

Patient and wound history

- 70-year-old male
- Medical history of type 1 diabetes mellitus with related peripheral neuropathy and retinopathy; peripheral vascular disease, chronic venous insufficiency (medicated), heart disease/failure, hypercholesterolemia and hyperthyroidism; ex-smoker with a history of asthma; indeterminant nodule was being monitored on his lung; high body mass index; osteoarthritis (hands)
- Below knee amputation on the left leg one year previous
- Traumatic wound, located on the right hallux; present for five weeks. Due to diabetes-related neuropathy, the patient had failed to notice the wound. The same patient presented with a venous leg ulcer which is featured in Case study 9
- Prior to the study, the wound had been treated with several advanced wound dressings (silver-containing hydroactive capillary action dressing and cadexomer iodine).

Intervention and treatment regime

- A detailed wound evaluation was completed at a baseline assessment and at 10 further scheduled visits over 70 days
- Wound dressings were changed twice weekly according to local clinical practice. At each dressing change throughout the study, the wound was cleansed with an antimicrobial wound irrigation solution and conservative sharp wound debridement was performed to achieve pin-point bleeding to stimulate wound healing. A barrier wipe was used to protect the peri-wound skin
- Prior to dressing application, the wound was coated with a thin film of Granulox®, then dressed with Mepilex® Border Flex (foam dressing). Two layers of Tubigrip® (elasticated tubular bandage) were applied from the toes to the knee to help with circulation for a co-existing lower leg ulcer.

Wound progression (photographs taken post-debridement/cleansing)

	Start of evaluation (Day 1)	Day 28	Day 42	Day 70
				
Wound area ¹	1.8cm ²	0.78cm ² (↓56.7%)	Not recorded	Healed
Signs of infection	None	None	None	-
Viable tissue	25%	Not recorded	100%	-
Exudation	None	None	None	-
Peri-wound	Healthy	Maceration ²	Healthy	Healthy ³
Pain score ⁴	0	0	0	-

¹Percentage changes in wound area relative to start of evaluation; ²At days 14 and 28, because of the dressings becoming wet while the patient showered, maceration of the peri-wound region was observed. In both instances the maceration was quickly resolved; ³At day 48, moderate blistering of the peri-wound region was observed. This was resolved after seven days of treatment and, thereafter, the peri-wound region remained relatively healthy but with mild dryness; ⁴On dressing removal based on a scale of 0 (no pain) to 10 (worst pain imaginable);

Perspective

- A five-week-old traumatic wound healed within 10 weeks of commencing treatment with Granulox®. The patient was then referred to a podiatrist for prevention management strategies for the foot and nail care
- Granulox® appeared to expediate the healing of a wound in a patient with underlying co-morbidities. As the patient was already receiving Granulox® for a co-existing leg ulcer, it made clinical sense to also commence the topical haemoglobin spray on the traumatic wound to facilitate healing in a timely manner
- The patient was pleased with how fast the wound healed compared to other wounds he had had in the past.



Sharon Cassidy, Clinical Nurse Specialist/Manager, SOS Nursing Wound Clinic, Christchurch, New Zealand



Case study 9. Venous leg ulcer

Patient and wound history

- 70-year-old male
- Medical history of type 1 diabetes mellitus with related peripheral neuropathy and retinopathy; peripheral vascular disease, chronic venous insufficiency (medicated), heart disease/failure, hypercholesterolemia and hyperthyroidism; ex-smoker with a history of asthma; indeterminant nodule was being monitored on his lung; high body mass index; osteoarthritis (hands)
- Below knee amputation on the left leg one year previous
- Longstanding venous leg ulcer. To allow easier movement at home, the patient kept the footplate of his wheelchair up. This caused repeated trauma and loss of skin to the back of his right leg, which, over time, developed into an ulcer. The same patient presented with a traumatic wound which is featured in Case study 8
- Prior to the study, the wound had been treated with several advanced wound dressings (silver-containing hydroactive capillary action dressing and cadexomer iodine).

Intervention and treatment regime

- A detailed wound evaluation was completed at a baseline assessment and regular follow-up visits over 170 days
- Wound dressings were changed twice weekly according to local clinical practice. At each dressing change throughout the study, the wound was cleansed with antimicrobial wound irrigation solution and conservative sharp wound debridement was performed to achieve pin-point bleeding to stimulate wound healing. A barrier wipe was used to protect the peri-wound skin
- Prior to dressing application, the wound was coated with a thin film of Granulox[®], then dressed with Exufiber[®] Ag+ (gelling fibre; primary dressing) and Mepilex[®] Border Flex (foam; secondary dressing). At day 43 of the study, Exufiber[®] Ag+ was discontinued (no longer required). Throughout the study, Mefix[®] (adhesive tape) was used for additional fixation together with Tubifast[®] (tubular retention bandage). The patient declined compression therapy.

Wound progression (photographs taken post-debridement/cleansing)

	Start of evaluation (Day 1)	Day 42	Day 84	Day 133
Wound area	1.0cm ²	Reduced	Reduced	Healed
Signs of infection	None	Suspected infection	None	-
Viable tissue	100%	100%	100%	100%
Exudate	None	None	None	-
Peri-wound	Healthy	Erythema	Healthy	Healthy (mild dryness)
Pain score ¹	0	0	0	-

¹On dressing removal based on a scale of 0 (no pain) to 100 (worst pain imaginable)

Perspective

- A longstanding venous leg ulcer healed within 19 weeks of commencing treatment with Granulox[®]
- Granulox[®] is an easy-to-use spray-on product that would be suitable for patients to provide 'self-care' in between wound reviews. To ensure that Granulox[®] remained 'in situ' when sprayed on the wound, consideration of the limb position was required
- Commenting on Granulox[®], the patient stated "I thought it did the job well. I was impressed how fast my wound healed once Granulox[®] was used".



Sharon Cassidy, Clinical Nurse Specialist/Manager, SOS Nursing Wound Clinic, Christchurch, New Zealand

Case study 10. Venous leg ulcer







Patient and wound history

- 66-year-old male
- Venous leg ulcer, located on the right medial ankle; present for four months
- Prior to the study, the ulcer had been treated with cadexomer iodine gel and an elastic compression bandage.

Intervention and treatment regime

- A detailed wound evaluation was completed at a baseline assessment and at four further scheduled visits over a period of 34 days
- Wound dressings were changed at each study visit according to local clinical practice
- At each dressing change throughout the study, mechanical debridement was performed using a pad moistened with an antimicrobial wound irrigation solution
- Prior to dressing application, the ulcer was coated with a thin film of Granulox®, then dressed (povidone iodine dressing and a sterile gauze).

Wound progression (photographs taken post-debridement/cleansing)

	Start of evaluation (Day 1)	Day 5	Day 18	Day 34
				
Wound area ¹	20.6cm ²	18.9cm ² (↓8.3%)	16.9cm ² (↓18.0%)	12.2cm ² (↓40.8%)
Wound depth	0.5cm	0.5cm	0.5cm	0.3cm
Signs of infection	None	None	None	None
Viable tissue	100%	100%	100%	100%
Exudate	Moderate; non-viscous; clear/serous	Low; non-viscous; clear/serous	Low; non-viscous; clear/serous	Low; non-viscous; clear/serous
Peri-wound	Healthy	Healthy	Healthy	Healthy
Pain score ²	8	7	6	4

¹Percentage changes in wound area relative to start of evaluation; ² On dressing removal based on a scale of 0 (no pain) to 10 (worst pain imaginable);

Perspective

- The condition of the ulcer improved following the introduction of Granulox® treatment
- Granulox® was easy and safe to use.



Marino Ciliberti, Director, Tissue Repair Company Network, Gragnano, Campania, Italy

Case study 11. Skin grafted leg ulcer







Patient and wound history

- 63-year-old female
- Leg ulcer, originating from a car accident; present for four months
- Patient presented following a skin graft procedure to the ulcer area
- Prior to the study, the ulcer had been treated with a povidone iodine dressing and an elastic compression bandage.

Intervention and treatment regime

- A detailed wound evaluation was completed at a baseline assessment (on completion of the skin graft procedure in the operating room) and at three further scheduled visits over a period of 25 days
- Wound dressings were changed at each study visit according to local clinical practice
- At each dressing change throughout the study, mechanical debridement was performed using a pad moistened with an antimicrobial wound irrigation solution
- Prior to all dressing applications between Day 1 and Day 25, the ulcer was coated with a thin film of Granulox®. After the application of Granulox®, an Avance® Solo bordered foam dressing was applied over the wound and connected to the negative pressure pump at the baseline, first (treatment day four) and second (treatment day 18) scheduled study visits. After 25 days, Avance® Solo negative pressure wound therapy system was discontinued and a povidone iodine dressing applied thereafter.

Wound progression (photographs taken post-debridement/cleansing)

	Start of evaluation (Day 1)	Day 4	Day 18	Day 25
				
Wound area ¹	54.0cm ²	36.1cm ² (↓33.1%)	0.5cm ² (↓99.9%)	Healed
Wound depth	0cm	0cm	0cm	-
Signs of infection	None	None	None	None
Viable tissue	100%	100%	100%	100%
Exudate	Low; non-viscous; clear/serous	Low; non-viscous; clear/serous	Low; non-viscous; clear/serous	Low; non-viscous; clear/serous
Peri-wound	Healthy	Healthy	Healthy	Healthy
Pain score ²	8	5	2	2

¹Percentage changes in wound area relative to start of evaluation; ²On dressing removal based on a scale of 0 (no pain) to 10 (worst pain imaginable)

Perspective

- The skin grafted ulcer healed within four weeks of commencing the treatment regime
- Granulox® was easy and safe to use.



Marino Ciliberti, Director, Tissue Repair Company Network, Gagnano, Campania, Italy



Concluding remarks

The preceding pages describe the successful management of some clinically challenging wounds. In all the cases presented, the introduction of Granulox® coincided with expedited progression, with complete healing of most of the wounds achieved in a timely manner. The findings also highlight the suitability of using topical haemoglobin spray alongside an array of different wound dressing types and other interventions such as skin grafting and negative pressure wound therapy. The successful outcomes described in these case reports are consistent with the findings of the clinical studies described earlier in this review.

References

- American Diabetes Association (ADA) (2023). Standards of Care in Diabetes – 2023. *J Clin Appl Res Ed* 46 (Suppl 1): S1-291
- Arenbergerova M, Engels P, Gkalpakiotis S et al (2013). Effect of topical haemoglobin on venous leg ulcer healing. *European Wound Management Association (EWMA) J* 13(2): 25-30
- Bishop A (2008) Role of oxygen in wound healing. *J Wound Care* 17(9): 399-402
- Chadwick P, Edmonds M, Fox A et al (2019) Expert panel report: the role of topical oxygen therapy in the management of diabetic foot ulcers. London: *The Diabetic Foot Journal*
- Da Vitoria Lobo ME, Weir N, Hardowar L et al (2022) Hypoxia-induced carbonic anhydrase mediated dorsal horn neuron activation and induction of neuropathic pain. *Pain* 163(11): 2264-79
- Demidova-Rice T, Hamblin M, Herman I (2012) Acute and impaired wound healing: Pathophysiology and current methods for drug delivery, part 1: Normal and chronic wounds: Biology, causes, and approaches to care. *Adv Skin Wound Care* 25(7): 304-14
- Dissemond J, Assenheimer B, Engels P et al (2017) M.O.I.S.T. – a concept for the topical treatment of wounds. *J German Soc Dermatol* 15(4): 443-4
- Dissemond J, Kroger K, Starck M et al (2015) Topical oxygen wound therapies for chronic wounds. *J Wound Care* 24(2): 53-63
- Elg F, Bothma G (2019) Cost-effectiveness of adjunct haemoglobin spray in the treatment of hard-to-heal wounds in a UK NHS primary care setting. *J Wound Care* 28(12): 844-9
- Frykberg RG, Banks J (2015) Challenges in the treatment of chronic wounds. *Adv Wound Care (New Rochelle)* 4(9): 560-82
- Gottrup F, Dissemond J, Baines C et al (2017) Use of oxygen therapies in wound healing. *J Wound Care* 26(5 Suppl): S1-43
- Hampton S (2015) How to address wound healing complications. *Nursing Times* 111(51-52): 22-25
- Han G, Ceilley R (2017) Chronic wound healing: a review of current management and treatments. *Adv Ther* 34(3): 599-610
- Hauser C. (1987) Tissue salvage by mapping of skin surface transcutaneous oxygen tension index. *Arch Surg* 122: 1128-30
- Hunt S, Elg F (2016) Clinical effectiveness of hemoglobin spray (Granulox®) as adjunctive therapy in the treatment of chronic diabetic foot ulcers. *Diabet Foot Ankle* 7:33101
- Hunt S, Elg F (2017) The clinical effectiveness of haemoglobin spray as adjunctive therapy in the treatment of chronic wounds. *J Wound Care* 26(9): 558-568
- Hunt S, Elg F, Percival SL (2018) Assessment of clinical effectiveness of haemoglobin spray as adjunctive therapy in the treatment of sloughy wounds. *J Wound Care* 27(4): 210-9
- International Working Group on the Diabetic Foot (IWGDF) (2023) *Guidelines on interventions to enhance healing of foot ulcers in people with diabetes. IWGDF Update 2023*. Available at: www.iwgdfguidelines.org (Accessed 29.02.2024)
- Kröger K, Gäbel G, Juntermanns B (2020) Assessment of acceptability and ease of use of haemoglobin spray (Granulox®) in the management of chronic wounds. *Chronic Wound Care Manag Res* 7: 1-10
- Ruthenborg RJ, Ban JJ, Wazir A et al (2014) Regulation of wound healing and fibrosis by hypoxia and Hypoxia-Inducible Factor-1. *Mol Cells* 37(9): 637-43
- Singh S, Young A, McNaught C (2017) The physiology of wound healing. *Surgery* 35(9): 473-7
- Strowitzki MJ, Ritter AS, Kimmer G, Schneider M (2019) Hypoxia-adaptive pathways: A pharmacological target in fibrotic disease? *Pharmacol Res* 147: 104364
- Timmons J (2006) Using case reports to aid reflective practice in wound care. *Br J Community Nurs* 11(3): S14-20
- Younis I (2020) Role of oxygen in wound healing. *J Wound Care* 29(5b Suppl): S4-10



WOUNDS | **INTERNATIONAL**